

Letter to the editor

Andrés Reyes Valdivia¹
África Duque Santos¹
Pablo Gallo González¹
Roberto Peromingo
Fresneda²
Julia Ocaña Guaita¹
Claudio Gandarias Zúñiga¹

Late aortic silver graft re-infection due to *Streptococcus milleri* group (*Streptococcus anginosus*). Case report and literature review

¹Department of Vascular and Endovascular Surgery. Ramón y Cajal University Hospital. Madrid, Spain.

²Department of General and Visceral Surgery. Ramón y Cajal University Hospital. Madrid, Spain.

Sir,

Streptococcus milleri group encounters three species: *Streptococcus anginosus*, *Streptococcus intermedius* and *Streptococcus constellatus*¹. These species are usually found in the normal flora of the urogenital tract, intestinal tract and oropharynx. When they are involved as pathogens in any disease, their main clinical manifestation is formation of abscesses². These can be located in any part of the body, and some reports demonstrate their capability to generate systemic infection. The brain, lungs, liver and bones are usual organs compromised when bacteraemia occur^{3,4}. Infection caused by *S. milleri* group has also been described in children and patients with some degree of immunodeficiency such as: the elderly or HIV (human immunodeficiency virus) patients⁵. Description of infection in vascular prosthesis have been done in some earlier reports, however, infection and re-infection has never been described in the same patient, to our knowledge.

An 84 year-old male, with history of coronary disease, presented to the emergency department with abdominal and lumbar tenderness, bilateral leg and feet pain and fever. This patient was initially treated 8 years before, in an elective setting, for a 5.5 cm. abdominal aortic aneurysm. At that time, a PTFE aortic tube was used for open repair. Five months surgery, patient was admitted in emergency room and diagnosed of aortoenteric fistula. Urgent in-situ aortic silver graft substitution was performed. Blood cultures revealed three positive tests for *S. anginosus* while prosthesis culture revealed one positive culture for the same microorganism. After surgery, patient was scheduled on antibiotics (amoxicillin/clavulanate three times daily) based on penicillin-sensitive culture. He continued on antibiotics for a total of 5 months after hospital discharge. No contact of any

segment of bowel or inflammation of any intestinal structure was found on CT-scans during follow up.

At the time of his actual disease presentation, patient blood pressure was stable with a slight tachycardia of 85 bpm. Due to intense leg and feet pain, vein duplex ultrasonography was made and revealed no signs of any thrombotic disease. Vascular exploration showed presence of all peripheral pulses but small petechiae were appreciated on his feet, suggesting embolic events. Urgent CT-scan confirmed aortoenteric fistula diagnosis with gas and thrombus inside the silver-dacron aortic graft (figure 1). Patient was scheduled for urgent repair due to symptomatic embolic events. In-situ aortic tube substitution with new silver Dacron graft impregnated with rifampicin was performed. Jejunal repair and intra-graft thrombectomy was done (figure 2) but patient died due to severe pulmonary edema and refractory hypotension. Blood, graft and thrombus cultures were all positive for *S. anginosus*, being again the causative of his graft re-infection.

Aortic graft infections are not frequent finding, being *Staphylococcus epidermidis* the most frequent microorganism when infection is diagnosed. This may be explained by surgical contamination as *S. epidermidis* can present as a late infection. Other microorganisms involved are *Staphylococcus aureus*, *Enterococcus* spp. or Enterobacteriaceae. Poli-microbial graft infection can also be found and this situation carries more risk for patient in terms of morbidity and mortality, as an immunosuppressive state may be suspected⁶. Traditional surgical treatment consists of staged extra-anatomic reconstruction (EAR) in a non-infected field using an axilo-bifemoral bypass as a first step, followed several days after by aortic graft removal⁷. However, some authors have reported high mortality rates caused by rupture of the aortic stump after EAR⁸ and other series have reported elevated rate of limb amputation caused by axilofemoral bypass thrombosis⁹. Explantation and in-situ reconstruction offers a better surgical resolution when feasible¹⁰. In-situ reconstruction can be made with cryopreserved allografts¹¹, vein grafts¹² or silver-dacron grafts¹³ as previous

Correspondence:
Andrés Reyes Valdivia. Department of Vascular and Endovascular Surgery. Ramón y Cajal University Hospital.
Ctra. Colmenar Viejo 9100. Postal Code 28034. Madrid, Spain.
Phone: 0034-913368656.
E-mail: cauzaza@hotmail.com

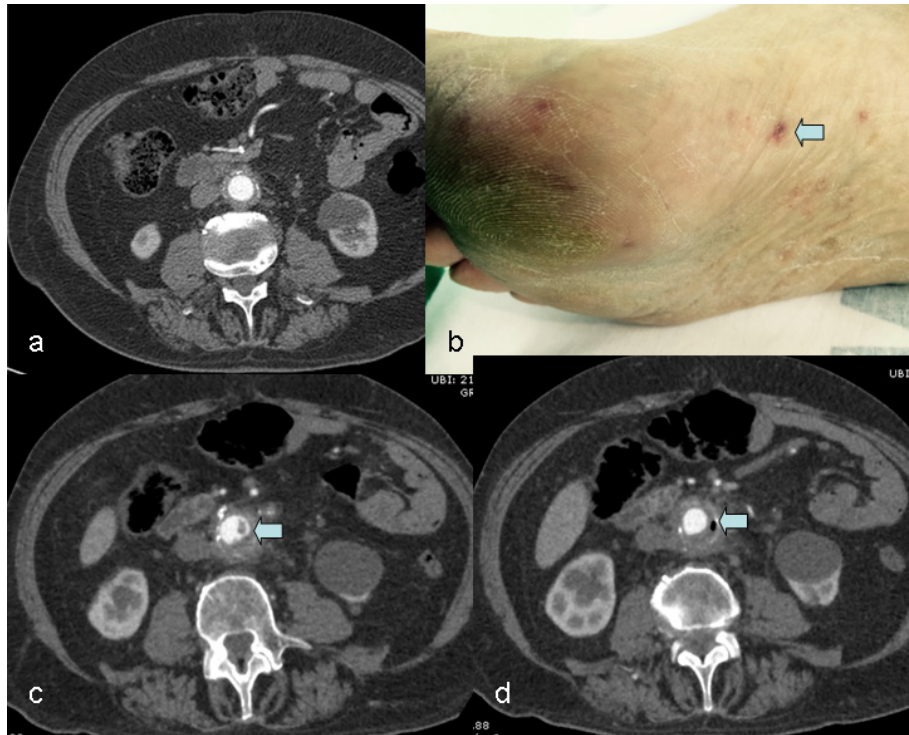


Figure 1 | A: Shows early CT-scan with normal aortic graft after first re-intervention. B: The image exhibits characteristic foot lesions of embolic events (arrow). C: Image shows thrombus inside the graft (arrow). D: The image shows gas inside the aortic graft (arrow).

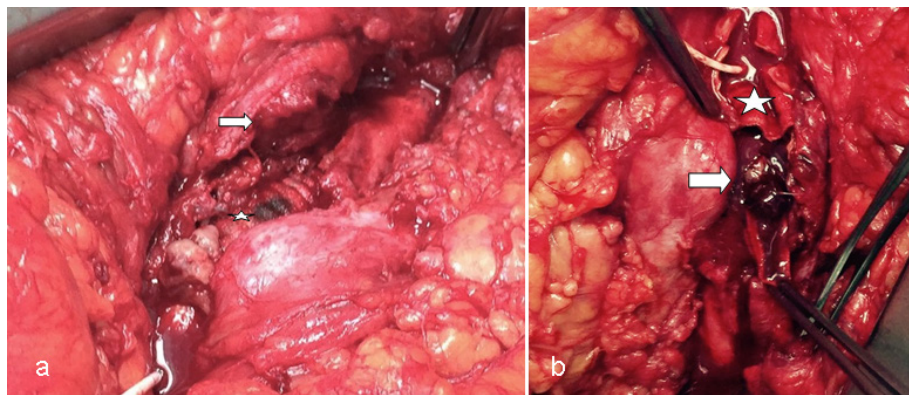


Figure 2 | A: The image indicates jejunal lesion contacting the silver graft (star). B: Image exhibits thrombus in the graft (arrow and star).

series have demonstrated their utility. Still, it carries high morbidity but reasonable mortality in the long term. When aortoenteric fistula is found mortality is even higher. Some series report mortality rates between 25% and 90%¹⁴. Complications such as gastrointestinal bleeding or severe sepsis can be rapidly encountered.

Recently, endovascular aortic repair (EVAR) has evolved, and some series describe its usefulness for the urgent setting in unstable patients. This technique is supposed to be used as

a bridge for open surgical treatment but is also being used as definitive treatment with adjunctive adjusted antibiotics treatment in very ill patients, with acceptable survival¹⁵.

Bonnet et al¹⁶ described in a previous report of 7 patients with infected aortic grafts due to *S. milleri* group microorganisms, four patients being caused by *S. anginosus*. Two (50%) of these patients died in the short term, one could not receive surgery and the other patient died 2 months after the surgical procedure. Both of them were around 60 years old. This report

suggests a therapeutic protocol based on removing infected prosthesis, creating a discharge stoma, closing the fistula and placing a new vascular prosthesis with the addition of optimal antimicrobial therapy with β -lactams.

S. anginosus is a very invasive and aggressive microorganism, which can rapidly widespread in the systemic circulation with generation of focal abscesses, described mainly in the liver, lung brain or even bones. Vascular grafts infections by these microorganisms have been reported in previous short reports, always been highly aggressive and with high morbidity and mortality even after treatment. The pathophysiology of abscesses formation is not well known, however a mucosal (usually gastrointestinal) alteration is mostly required. Histolytic enzymes, extra cellular immunosuppressive materials, the polysaccharide capsule and the ability to bind to fibronectin are other conditions associated to its pathogenicity. In this case, and what makes this case unique, is that patient was infected two times by the same microorganism in an 8 year period, both of them presenting as aortoenteric fistula. The second time in a silver Dacron graft which is described to be highly resistant to infection, this emphasize the highly infective condition of this microorganism and the reason why aggressive antibiotic long-term treatment is required even after surgical treatment is done. Open surgical approach decision was based on the hemodynamic stable situation of the patient with nearly normal blood tests (slight leucocytosis alone). We believe infection, in this case, could be due to contamination of the surgical field and a very slow microorganism growth with secondary infection of the prosthesis, as it was silver impregnated.

FUNDING

Authors declare no financial support for this study.

CONFLICTS OF INTEREST

The authors declare no conflicts of interest

REFERENCES

1. Whiley RA, Beighton D: Emended descriptions and recognition of *Streptococcus constellatus*, *Streptococcus intermedius* and *Streptococcus anginosus* as distinct species. *Int J Syst Bacteriol* 1991; 41: 1-5.
2. Suzuki H, Hase R, Otsuka Y, Hosokawa N. Bloodstream infections caused by *Streptococcus anginosus* group bacteria: A retrospective analysis of 78 cases at a Japanese tertiary hospital *J Infect Chemother* 2016; 22:456-60.
3. Kim SH, Park MS, Song SH, Lee HJ, Choi EH. Hematogenous osteomyelitis caused by *Streptococcus anginosus* group in a previously healthy child. *Pediatr Int* 2010; 52:e209-11.
4. Sunwoo BY, Miller WT Jr. *Streptococcus anginosus* infections: crossing tissue planes. *Chest*. 2014;146(4):e121-5.
5. Yassin M, Yadavalli GK, Alvarado N, Bonomo RA. *Streptococcus anginosus* (*Streptococcus milleri* Group) Pyomyositis in a 50-Year-Old Man with Acquired Immunodeficiency Syndrome: Case Report and Review of Literature. *Infection*. 2010; 38:65-8.
6. O'Connor S, Andrew P, Batt M, Becquemain JP: A systematic review and meta-analysis of treatments for aortic graft infection. *J Vasc Surg* 2006; 44: 38-45.
7. Seeger JM, Pretus HA, Welborn MB, Ozaki CK, Flynn TC, Huber TS. Long-term outcome after treatment of aortic graft infection with staged extra-anatomic bypass grafting and aortic graft removal. *J Vasc Surg* 2000; 32:451-9.
8. Kuestner LM, Reilly LM, Jicha DL, Ehrenfeld WK, Goldstone J, Stoney RJ. Secondary aortoenteric fistula: contemporary outcome with use of extraanatomic bypass and infected graft excision. *J Vasc Surg* 1995; 21:184-95.
9. Quiñones-Baldrich WJ, Hernandez JJ, Moore WS. Long-term results following surgical management of aortic graft infection. *Arch Surg* 1991;126:507-11.
10. Oderich GS, Bower TC, Cherry Jr KJ, Panneton JM, Sullivan TM, Noel AA, et al. Evolution from axillofemoral to in situ prosthetic reconstruction for the treatment of aortic graft infections at a single center. *J Vasc Surg* 2006; 43(6): 1166-74.
11. Bisdas T, Bredt M, Pichlmaier M, Aper T, Wilhelmi M, Bisdas S, et al. Eight-year experience with cryopreserved arterial homografts for the in situ reconstruction of abdominal aortic infections. *J Vasc Surg* 2010; 52:323-30.
12. Ali AT, Modrall JG, Hocking J, Valentine RJ, Spencer H, Eidt JF, et al. Long-term results of the treatment of aortic graft infection by in situ replacement with femoral popliteal vein grafts. *J Vasc Surg* 2009; 50:30-9.
13. Delva JC, Déglise S, Bérard X, Dubuisson V, Delva F, Stecken L et al. In-situ revascularisation for secondary aorto-enteric fistulae: the success of silver-coated Dacron is closely linked to a suitable bowel repair. *Eur J Vasc Endovasc Surg* 2012; 44:417-24.
14. Sierra J, Kalangos A, Faidutti B, Christenson JT: Aorto-enteric fistula is a serious complication to aortic surgery. Modern trends in diagnosis and therapy. *Cardiovasc Surg* 2003; 11:185-8.
15. Kakkos SK, Antoniadis PN, Klonaris CN, Papazoglou KO, Giannoukas AD, Matsagkas MI, et al. Open or endovascular repair of aortoenteric fistulas? A multicentre comparative study. *Eur J Vasc Endovasc Surg* 2011; 41:625-34.
16. Bonnet EP, Arista S, Archambaud M, Boot B, Clave D, Massip P, Marchou B. *Streptococcus milleri* group infection associated with digestive fistula in patients with vascular graft: report of seven cases and review. *Infection* 2007; 35:182-5.