

Letter to the Editor

Alejandro Úbeda-Iglesias¹
Antonio Sánchez-Porto²
Laura Alonso-Romero³
Javier Casas-Ciria²
José María Eiros⁴

Severe community-acquired pneumonia caused by *Rothia mucilaginosa* in an immunocompetent patient

¹Unidad de Cuidados Intensivos, Hospital "Punta Europa", Algeciras,

²Hospital de La Línea de la Concepción

³Hospital Quirón "Campo de Gibraltar"

⁴Facultad de Medicina de Valladolid

Sir, *Rothia mucilaginosa*, previously *Stomatococcus mucilaginosus*, is an aerobic gram-positive coagulase-negative capped coccus of the family *Micrococcaceae*. It is found in the upper respiratory tract and oropharynx as part of the normal microbiota. It is considered an opportunistic pathogen and it can cause infections, especially bacteraemia in neutropenic or immunosuppressed patients, and rarely in immunocompetent patients¹. *R. mucilaginosa* is generally considered to be a contaminant in respiratory tract infection specimen. Moreover, lower respiratory tract infections by this organism are rare and few cases have been diagnosed by recovery of *R. mucilaginosa* from the bronchoscopic specimens so it could be difficult to determine the clinical significance of its isolation in respiratory samples.

We present a case of severe community-acquired pneumonia (CAP) caused by *R. mucilaginosa* in an immunocompetent patient with chronic obstructive pulmonary disease (COPD), who required ICU admission.

A 56 year old woman, smoker of a pack of cigarettes per day, with diagnosis of COPD and bronchiectasis, without adherence to prescribed treatment.

The patient went to the emergency department for worsening of her usual dyspnea, fatigue and general discomfort during the previous 4 days. Upon arrival, she presented atrial fibrillation with rapid ventricular response, blood pressure was 190/100 mmHg and respiratory failure was objectified. The patient was admitted to start noninvasive mechanical ventilation (NIV) and treatment with amiodarone and nitroglycerin.

In blood test highlights: a white blood cell count of 19.700/mL (94% neutrophils), C-reactive protein level was elevated at 249.1 mg/L. Venous blood gases: pH 7.26, pCO₂ 80 mmHg, bicarbonate 35.9 mmol/L.

A chest radiography (figure 1) was performed, and it was objectified an alveolar infiltration in the right upper lobe, so empirical antibiotic therapy with ceftriaxone and levofloxacin was started.

The patient presented clinical deterioration with clinical signs of respiratory failure in the first 12 hours of stay in Emergency Department, so she was transferred to Intensive Care Unit (ICU).

At ICU admission, the patient was tachycardic at 100 beats/minute, with 81% SatO₂ on NIV, decreased breath

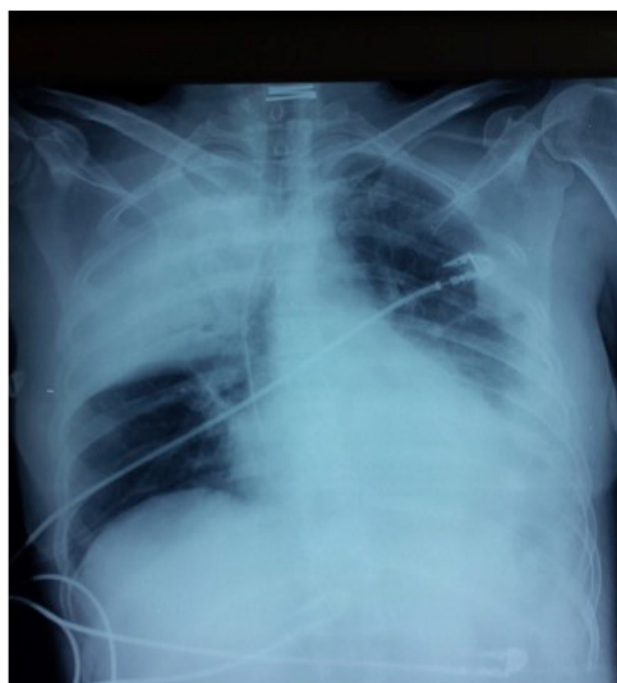


Figura 1 Chest radiography on arrival to the emergency department.

Correspondence:
Alejandro Úbeda-Iglesias
Unidad de Cuidados Intensivos. Hospital Punta de Europa.
Ctra. Getares, s/n. 11207 Algeciras (Cádiz).
Tfno.: 956025218.
Fax : 956025218.
E-mail: alubeda@gmail.com

sounds with scattered crackles and lip cyanosis. Endotracheal intubation and mechanical ventilation connection was necessary due to refractory respiratory failure. The patient presented progressive and refractory hypotension requiring initiation of noradrenaline. Dobutamine was added due to a low overall contractility in echocardiography (ejection fraction estimated of 30%). Blood culture and bronchial aspirate (BAS) were sent.

The BAS specimen was used for quantitative culture. Acid-fast bacilli stain and culture, respiratory virus PCR, *Mycobacterium tuberculosis* PCR and fungus culture of the BAS specimen were all negative.

The third day of ICU stay, *R. mucilaginosa* was isolated in pure BAS culture. The colony counts were $>10^5$ colony-forming units (CFU) /mL. The identification was made by MicroScan® Walk Away (Dade Behring) and mass spectrometry MALDI-TOF (Bruker, F. Soria, Spain). The sensitivity was determined by performing the minimum inhibitory concentration by Etest (bioMérieux, Marcy l'Etoile, France) on blood agar plates at 37°C in oven with 5% CO₂ for 24 hours.

The minimum inhibitory concentrations of the tested antimicrobials were 0.05 mg/L for penicillin, 0.06 mg/L for ampicillin, ≤ 0.25 mg/L for ceftriaxone, > 2 mg/L for levofloxacin and ≤ 0.5 mg/L for meropenem.

Levofloxacin treatment was stopped. The patient presented progressive improvement; extubation and withdrawal of amines were achieved after 72 hours in ICU.

During the following days, the patient needed intermittent NIV to treat respiratory acidosis and was transferred to internal medicine ward after 9 days in ICU. She was discharged after 12 days in hospital with complete resolution of CAP.

We present a case of pneumonia in an immunocompetent patient in which *R. mucilaginosa* was the only organism isolated from the BAS culture.

In this case, *R. mucilaginosa* was isolated in pure culture of BAS so it was considered as the causative agent of the pneumonia. However, it is difficult to determine the clinical significance of *R. mucilaginosa* when it is isolated in respiratory specimens, particularly in immunocompetent patients.

There are few published cases of respiratory infections by *R. mucilaginosa*, and in most of them the diagnosis was based on isolations from sputum cultures². Ramos et al³ reviewed isolates of *R. mucilaginosa* in their hospital for 4 years and they found 20 cases of infection due to this germ, being mostly superinfected bronchiectasis (n=10) and only one pneumonia based on isolation of *R. mucilaginosa* in one sputum culture.

In immunocompromised patients, Cho et al⁴ showed that the predominant growth of *R. mucilaginosa* in invasive respiratory samples (bronchoalveolar lavage) was not likely due to contamination by the normal oropharyngeal flora, so bronchoscopic specimens are recommended in these situations.

In our case, the bacterial translocation from the mouth in a patient with COPD and low capacity to cough as well as the presence of microaspirations could have been the main pathophysiological mechanisms of CAP. The isolation of *R.*

mucilaginosa in patients with COPD and bronchiectasis even in immunocompetent patients should be taken into account in lower respiratory tract infections⁵, especially if, as in our case, the isolation is produced in a sample of good quality and pure culture.

In this case, the quantitative cultures from the BAS specimen showed more than 10⁵ CFU/mL, which gave a strong support for the diagnosis of CAP by *R. mucilaginosa*. The identification by mass spectrometry (MALDI-TOF) helped us to evaluate *R. mucilaginosa* as etiologic agent of CAP in immunocompetent patient.

CONFLICTS OF INTEREST

The authors declare no conflict of interest

REFERENCES

1. Ramanan P, Barreto JN, Osmon DR, Tosh PK. *Rothia* bacteremia: a 10-year experience at Mayo Clinic, Rochester, Minnesota. *J Clin Microbiol* 2014; 52: 3184-9.
2. Baeza-Martinez C, Zamora-Molina L, Garcia-Sevilla R, Gil-Carbonell J, Ramos-Rincon JM, Martin-Serrano C. Neumonía por *Rothia mucilaginosa* en paciente inmunocompetente. *Arch Bronconeumol* 2014; 50: 493-5.
3. Ramos JM, Mateo I, Vidal I, Rosillo EM, Merino E, Portilla J. Infección por *Rothia mucilaginosa*. ¿Un patógeno respiratorio?. *Enferm Infecc Microbiol Clin* 2014; 32: 306-9.
4. Cho EJ, Sung H, Park SJ, Kim MN, Lee SO. *Rothia mucilaginosa* pneumonia diagnosed by quantitative cultures and intracellular organisms of bronchoalveolar lavage in a lymphoma patient. *Ann Lab Med* 2013; 33:145-9.
5. Maraki S, Papadakis IS. *Rothia mucilaginosa* pneumonia: a literature review. *Infect Dis (Lond)* 2015; 47: 125-9.