

Letter to the editor

Joaquín Bartolomé-Álvarez¹
Juan Antonio Sáez-Nieto²
Ángel Escudero-Jiménez¹
Nuria Barba-Rodríguez³
Jorge Galán-Ros¹
Gema Carrasco²
María Paz Muñoz-Izquierdo³

Cutaneous abscess due to *Gordonia bronchialis*: case report and literature review

¹Servicio de Microbiología, Complejo Hospitalario Universitario de Albacete. Spain.

²Laboratorio de Taxonomía. Área de Bacteriología. Centro Nacional de Microbiología. Instituto de Salud Carlos III. Madrid. Spain.

³Centro de Salud de Almansa. Almansa. Spain.

Sir,

The genus *Gordonia* is currently composed of 38 species mainly isolated from soil, sludge and other environments. Eight of them have been isolated from clinical samples (*G. terrae*, *G. aichiensis*, *G. sputi*, *G. bronchialis*, *G. otitidis*, *G. iterans*, *G. effusa*, and *G. araii*). This genus is of increasing industrial interest due to the metabolic capabilities of many of its members. These few species have been found to cause infections in humans¹. Furthermore other species have been recently identified in the Laboratory of Taxonomy from various clinical samples where there were previously not detected (*G. polyisoprenivorans* and *G. alkanivorans*, were isolated from blood, sputum, abscess and wounds) [Sáez Nieto et al. Unpublished data].

Gordonia bronchialis was originally isolated from human clinical specimens². Since then, a number of case reports have been published³⁻¹⁴, but a complete understanding of the pathogenic potential of *G. bronchialis* is still lacking.

Here we report on a patient who developed an abscess by *G. bronchialis* at the site of a needle injection and review the previously reported cases of infection by this species.

A 50-year old nurse gave herself an injection with a nativist product in the right upper quadrant of the right buttock. She was previously healthy with no medical history. One month later, she noted a hard, warm, painful mass at the site of injection. An aspirate of the lesion was sent to the microbiology laboratory for bacterial culture. The patient was prescribed oral amoxicillin-clavulanate for five days, and the induration resolved. Gram stain of the aspirate showed abundant polymorphonuclear leukocytes and very few intracellular branched grampositive bacilli. Cultures on chocolate and blood

agar grew a few dry, nonhaemolytic, yellow-orange coloured colonies after 48 hours of incubation. The colonies became orange-salmon with prolonged incubation. Anaerobic plate (Schaedler agar) was negative. The organism was a weakly acid-fast grampositive bacillus which also showed rare branching. It was initially identified as an aerobic actinomycete. The confirmation of isolate identity was obtained by sequencing of a fragment of 1,202 bp from 16s rRNA using a previously reported method¹⁵. The sequence obtained showed a 100% homology with the *G. bronchialis* sequences deposited in GenBank, accession nº NR074529, HQ316192 among others.

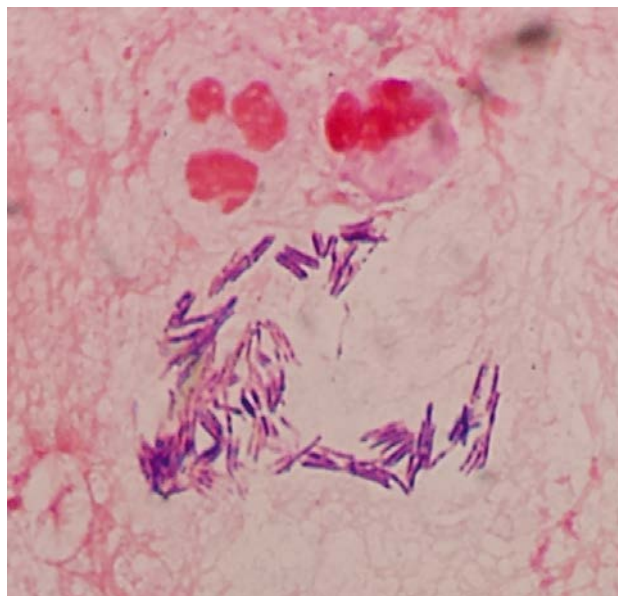


Figura 1 Gram staining of the abscess aspirate showing grampositive bacilli in parallel arrays (original magnification, x1,000).

Correspondence:

Joaquín Bartolomé-Álvarez
Servicio de Microbiología. Hospital General Universitario de Albacete.
C/ Hermanos Falcó, 37; 02006 Albacete. Spain.
E-mail: jbartolome@sescam.jccm.es

Table 1 Case reports of human infections due to *Gordonia bronchialis*.

Type of infection	Number of patients	Age	Sex	Underlying condition	Year of publication
Sternal wound	7 (cluster)	51-68	Male	Sternotomy	1991 ³
Bacteraemia	1	58	Female	Sequestered lung, diabetes	2004 ⁴
Breast abscess	1	43	Female	None	2005 ⁵
Ventriculitis	1	45 days	N.s.	Intraventricular shunt, premature neonate	2007 ⁶
Bacteraemia, pleural infection	1	52	Female	Splenectomy, chronic pleuropulmonary disease	2011 ⁷
Tibial osteomyelitis	1	22	Female	Surgery, hardware implantation	2012 ⁸
Sternal wound	3 (cluster)	56-80	Male	Sternotomy	2012 ⁹
Sternal osteomyelitis	1	76	Female	Sternotomy	2013 ¹⁰
Sternal osteomyelitis	1	69	Female	Sternotomy, diabetes	2014 ¹¹
Sternal wound	3 (cluster)	N.s.	N.s.	Sternotomy	2014 ¹²
Peritonitis	1	70	Male	Continuous ambulatory peritoneal dialysis, diabetes	2014 ¹³
Peritonitis	1	64	Female	Continuous ambulatory peritoneal dialysis	2015 ¹⁴
Abscess	1	50	Female	Prior needle injection	This case

N.s.: not specified.

Table 2 Susceptibility of *G. bronchialis* isolates to antimicrobial agents.

Antibiotic	No. of susceptible isolates /No. tested isolates ^a	% susceptible isolates
Imipenem	20/20	100
Gentamicin	13/13	100
Ciprofloxacin	20/21	95
Amikacin	19/20	95
Linezolid	18/19	95
Tobramycin	16/17	94
Amoxicillin-clavulanic acid	7/7	100
Ceftriaxone	8/8	100
Minocycline	14/17	82
Cefepime	11/14	79
TMP-SMX	4/19	21

^aData are from references 3-5,7,8,10,11,14,16,18, and the present case.

In the following 2-3 months the affected area enlarged again and pain returned. The abscess was thoroughly drained by needle aspiration, and a new sample was sent for culture. Gram stain of aspirate showed many inflammatory cells and grampositive bacilli arranged in clusters in which the bacilli frequently showed a parallel orientation (figure 1). Culture of the abscess aspirate grew moderate colonies of *G. bronchialis*. Antimicrobial susceptibility testing was done using E-test. The

organism was found to be susceptible to amoxicillin-clavulanic acid, ciprofloxacin, imipenem, amikacin, cefotaxime, and linezolid, and resistant to trimethoprim-sulfamethoxazole.

The patient was treated with oral amoxicillin-clavulanate for 10 days, and the lesion healed, with residual hyperpigmentation.

G. bronchialis was initially isolated from sputum of patients with cavitary tuberculosis and bronchiectasis, but there was no information about the clinical significance of these isolates². In 1991, *G. bronchialis* was reported as a cause of sternal wound infection³, and since then 23 cases of human infection has been documented³⁻¹⁴ (table 1). Three outbreaks of sternal wound infection account for 13 of the 23 reported cases. In two outbreaks, a colonized nurse was identified as the source of the infection^{3,9}. In 19 of 23 cases, *G. bronchialis* infection followed a surgical procedure that resulted in the implantation of foreign material: surgical wires in sternotomy^{3,9-12}, a polymer screw⁸, an intraventricular shunt⁶, and a peritoneal dialysis catheter^{13,14}. Two cases of bacteraemia in patients with chronic pulmonary disease and immunocompromise (diabetes in one patient and splenectomy in another) have been reported^{4,7}. A breast abscess occurred in an immunocompetent female without known risk factors⁵. In our case, a previously healthy immunocompetent female developed an abscess following a needle injection.

In other studies, the significance of isolation of *G. bronchialis* from human clinical samples is unclear or not documented. Aoyama et al.¹⁶ described antimicrobial susceptibility of 13 clinical isolates of *G. bronchialis*, but provided no clinical details of the patients. Brust et al.¹⁷ reported on the isolation of *G. bronchialis* from blood cultures of a patient with hyper-

osmolar coma, but in this case *G. bronchialis* was finally considered to be either a contaminant or a colonizer. Ramanan et al.¹⁸ isolated *G. bronchialis* from blood cultures (one out of two sets) in a patient with herpes simplex virus encephalitis, but the clinical significance of this finding was not clear.

Most of the cases in table 1 were published in recent years, in parallel with the increased use of 16S rRNA gene sequencing and matrix-assisted laser desorption ionization-time of flight mass spectrometry (MALDI-TOF MS) for bacterial identification in clinical laboratories. Infection by *G. bronchialis* has probably been underdiagnosed in the past due to the difficulties in identifying *Gordonia* species by conventional biochemical methods.

In the original description of the genus *Gordonia*, Tsukamura stated that cells of *G. bronchialis* were rod-shaped and showed a compact grouping (like cord)². This description of *G. bronchialis* cells closely resembles the appearance of the gram-positive bacilli we observed in the Gram stain of the 2nd clinical specimen (figure 1). Figure 1 shows that the characteristic cellular arrangement of *G. bronchialis* can also be observed in vivo.

The optimal antibiotic therapy for *Gordonia* infections is unknown. The patients in table 1 were treated with a variety of antimicrobial regimens, usually for several weeks or months, with good outcome in most cases³⁻¹⁴. Table 2 summarizes antibiotic susceptibility results for isolates that were reported to date. Imipenem, gentamicin, amikacin, tobramycin, ciprofloxacin, linezolid, amoxicillin-clavulanic acid, and ceftriaxone showed good *in vitro* activity against >90% of tested isolates^{3-5,7,8,10,11,14,16,18}. In contrast, trimethoprim-sulfamethoxazole had poor activity, as it has been reported for other *Gordonia* species¹⁹.

In summary, *G. bronchialis* is an emerging cause of human infections. Most of the published cases occurred in immunocompetent patients and were foreign body or medical device related infections. Careful attention to the characteristic appearance of *G. bronchialis* in Gram stain and cultures is needed in order to correctly identify this bacterium in clinical samples.

FUNDING

No funding to declare.

CONFLICTS OF INTEREST

None to declare.

REFERENCES

- Drzyzga O. The strengths and weaknesses of *Gordonia*: a review of an emerging genus with increasing biotechnological potential. *Crit Rev Microbiol* 2012; 38: 300-16.
- Tsukamura M. Proposal of a new genus, *Gordonia*, for slightly acid-fast organisms occurring in sputa of patients with pulmonary disease and in soil. *J Gen Microbiol* 1971; 68: 15-26.
- Richet HM, Craven PC, Brown JM, Lasker BA, Cox CD, McNeil MM, et al. A cluster of *Rhodococcus (Gordonia) bronchialis* sternal-wound infections after coronary-artery bypass surgery. *N Engl J Med* 1991; 324: 104-9.
- Sng LH, Koh TH, Toney SR, Floyd M, Butler WR, Tan BH. Bacteremia caused by *Gordonia bronchialis* in a patient with sequestered lung. *J Clin Microbiol* 2004; 42: 2870-1.
- Werno AM, Anderson TP, Chambers ST, Laird HM, Murdoch DR. Recurrent breast abscess caused by *Gordonia bronchialis* in an immunocompetent patient. *J Clin Microbiol* 2005; 43: 3009-10.
- Blaschke AJ, Bender J, Byington CL, Korgenski K, Daly J, Petti CA, et al. *Gordonia* species: emerging pathogens in pediatric patients that are identified by 16S ribosomal RNA gene sequencing. *Clin Infect Dis* 2007; 45: 483-6.
- Johnson JA, Onderdonk AB, Cosimi LA, Yawetz S, Lasker BA, Bolcen SJ, et al. *Gordonia bronchialis* bacteremia and pleural infection: case report and review of the literature. *J Clin Microbiol* 2011; 49: 1662-6.
- Siddiqui N, Toumeh A, Georgescu C. Tibial osteomyelitis caused by *Gordonia bronchialis* in an immunocompetent patient. *J Clin Microbiol* 2012; 50: 3119-21.
- Wright SN, Gerry JS, Busowski MT, Klochko AY, McNulty SG, Brown SA, et al. *Gordonia bronchialis* sternal wound infection in 3 patients following open heart surgery: intraoperative transmission from a healthcare worker. *Infect Control Hosp Epidemiol* 2012; 33: 1238-41.
- Vasquez MA, Marne C, Villuendas MC, Arazo P. Subacute sternal osteomyelitis caused by *Gordonia bronchialis* after open-heart surgery. *Enferm Infecc Microbiol Clin* 2013; 31: 559-60.
- Chang JH, Ji M, Hong HL, Choi SH, Kim YS, Chung CH, et al. Sternal osteomyelitis caused by *Gordonia bronchialis* after open-heart surgery. *Infect Chemother* 2014; 46: 110-4.
- Nguyen DB, Gupta N, Aboud-Daoud A, KleKamp BG, Rhone C, Winston T, et al. A polymicrobial outbreak of surgical site infections following cardiac surgery at a community hospital in Florida, 2011-2012. *Am J Infect Control* 2014; 42: 432-5.
- Ma TK, Chow KM, Kwan BC, Lee KP, Leung CB, Li PK, et al. Peritoneal-dialysis related peritonitis caused by *Gordonia* species: report of four cases and literature review. *Nephrology* 2014; 19: 379-83.
- Lam JYW, Wu AKL, Leung W-S, Cheung I, Tsang C-C, Chen JHK, et al. *Gordonia* species as emerging causes of continuous-ambulatory-peritoneal-dialysis-related peritonitis identified by 16S rRNA and *secA1* gene sequencing and matrix-assisted laser desorption ionization-time of flight mass spectrometry (MALDI-TOF MS). *J Clin Microbiol* 2015; 53: 671-6.
- Drancourt M, Bollet C, Carlioz A, Martelin R, Gayral JP, Raoult D. 16S ribosomal DNA sequence analysis of a large collection of environmental and clinical unidentifiable bacterial isolates. *J Clin Microbiol* 2000; 38: 2623-30.
- Aoyama K, Kang Y, Yazawa K, Gono T, Kamei K, Mikami Y. Characterization of clinical isolates of *Gordonia* species in Japanese clinical samples during 1998-2008. *Mycopathologia* 2009; 168: 175-83.

17. Brust JCM, Whittier S, Scully BE, McGregor CC, Yin MT. Five cases of bacteraemia due to *Gordonia* species. *J Med Microbiol* 2009; 58: 1376-8.
18. Ramanan P, Deziel PJ, Wengenack NL. *Gordonia* bacteremia. *J Clin Microbiol* 2013; 51: 3443-7.
19. Moser BD, Pellegrini GJ, Lasker BA, Brown JM. Pattern of antimicrobial susceptibility obtained from blood isolates of a rare but emerging human pathogen, *Gordonia polyisoprenivorans*. *Antimicrob Agents Chemother* 2012; 56: 4991-3.