

## Letter to the Editor

Marta Díaz-Menéndez<sup>1</sup>  
Marina Alguacil-Guillén<sup>2</sup>  
Ivan Bloise<sup>2</sup>  
Marta García-Pallarés<sup>3</sup>  
Jesús Mingorance<sup>2</sup>

# A case of otitis externa caused by non-O1/non-O139 *Vibrio cholerae* after exposure at a Mediterranean bathing site

<sup>1</sup>Infectious Diseases Unit, Department of Internal Medicine. University Hospital La Paz-Carlos III, Madrid, Spain.

<sup>2</sup>Department of Microbiology and Parasitology. University Hospital La Paz-Carlos III, Madrid, Spain.

<sup>3</sup>Department of Otolaryngology, University Hospital La Paz-Carlos III, Madrid, Spain

### Article history

Received: 16 March 2018; Accepted: 5 April 2018

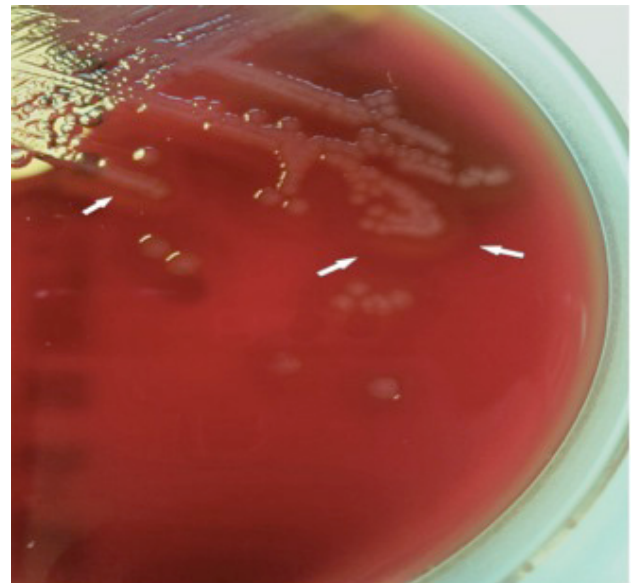
Sir,

*Vibrio cholera* is a gram-negative rod that is ubiquitous in marine environments (mostly estuaries and coastal areas) and freshwater. Although more than 200 serogroups of *Vibrio* have been identified, only a small subset of *V. cholera* strains (O1 and O139 mainly) are responsible for enteric disease and outbreaks that cause nearly 95,000 deaths every year [1]. *Vibrio* strains non-O1/non-O139 (VCN) are especially associated with mild gastroenteritis but also with bacteremia, and wound, ear and other site infections [2]. We report a rare case of otitis externa due to non-O1/non-O139 *Vibrio cholera* acquired after exposure in Mediterranean waters. We take advantage of this atypical circumstance to make a review of cases reported in Spain.

In September 2017, a 35-year-old Spanish male was referred to an otolaryngologist due to acute otitis externa. His past medical history was unremarkable except for bilateral recurrent otitis media in childhood that required of tympanostomy tubes. Since then, he has had no other ear infections until early in 2017, when he began to suffer from several periodic otitis externa episodes. In August of that year, he started with a smelly purulent discharge from his left ear, associated with otalgia with no other accompanying symptoms. Otolaryngoscopic examination revealed an intact tympanic membrane and an otic swab was taken. Empiric therapy with ciprofloxacin eardrops was prescribed for 10 days and ear aspirations were performed twice during the treatment period. He recalled having taken a 15-day trip to Tarragona (Catalonia) in July 2017, where he bathed in the sea. He denied having travelled outside of Spain in the past 5 years.

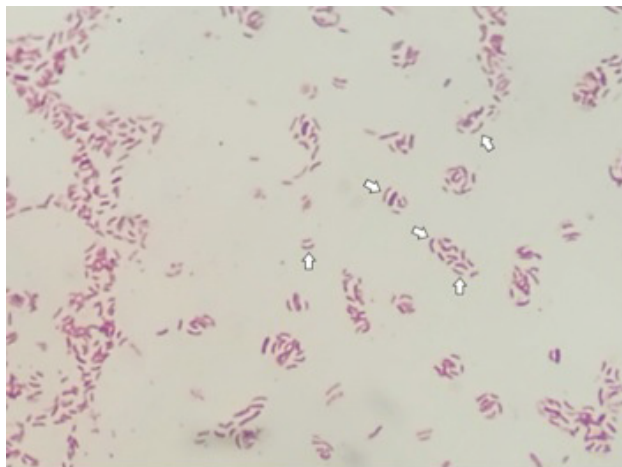
The swab was cultivated on sheep blood agar, chocolate

agar, McConkey agar and Chromagar plates, which were incubated at 37°C in an atmosphere containing 5% CO<sub>2</sub>. After the first 24 hours, colonies grew in all the bacterial culture media, and haemolysis was observed on the blood agar plate (figure 1). Gram staining showed gram-negative curved rods (figure 2) and there was a positive oxidase test result. The organism was identified as *Vibrio cholera* by Matrix-Assisted Laser Desorption Ionization Time-Of-Flying Mass Spectrometry (MALDI-TOF MS) using the MALDI-Biotyper 3.1 software (Bruker Daltonik GmbH, Bremen, Germany). The identification of *V. cholerae* was further confirmed by pyrosequencing three variable regions (V1, V3, and V6) of the 16S rRNA gene with



**Figure 1** Haemolytic colonies of *V. cholerae* on sheep blood agar after 24 hours of incubation. White arrows show the haemolytic halo.

Correspondence:  
Marta Díaz-Menéndez  
Infectious Diseases Unit, Department of Internal Medicine.  
University Hospital La Paz-Carlos III, C/Sinesio Delgado, nº 10. 28029, Madrid (Spain).  
Tel: +0034 628 337 899.  
Fax: + 0034 917 336 614  
Email: marta.diazmenendez@gmail.com



**Figure 2** Gram-negative curved rods (white arrows show comma-shaped bacillus) of *V. cholerae* on colony Gram stain.

a PyroMarkID system (Qiagen, Germany) [3]. The isolate was ultimately identified in Madrid by Spain's National Microbiology Reference Laboratory (Centro Nacional de Microbiología) as *V. cholerae* non-O1/non-O139, cholera toxin-negative. Susceptibility tests were performed by E-test® (bioMérieux, France) and interpreted according to CLSI breakpoints for *V. cholerae* [4]. The strain showed susceptibility to cefotaxime, ceftazidime, ciprofloxacin, levofloxacin, trimethoprim-sulfamethoxazole, minocycline and tetracycline.

Two weeks after beginning the treatment, an additional swab resulted negative for *V. cholera* and the patient had a complete recovery.

There have only been two previously described cases of VCN causing gastroenteritis [5] and skin infection [6] in immunocompromised patients in Spain. Nevertheless, VCN have previously been identified in both salt and fresh water in the Mediterranean Spanish coast [7], thus it is most likely that infections by VCN are underdiagnosed.

VCN infections are commonly associated with immunosuppression and very few cases have been described in healthy people. The patient described was an immunocompetent young male with a history of chronic ear infections, which may have contributed to the VCN infection [8].

Routine ear swabs are not carried out unless there are recurrent episodes of severe otitis externa, chronic otitis, immunosuppressed patients or patients who do not respond to initial therapy [9]. Thus, it is possible that there might have been several other cases of infections due to VCN that could have gone unnoticed and resolved after empiric treatment.

The current case occurred in August, during the swimming season and holiday period in Spain, which coincides with warmer sea temperatures. Recent studies have linked climatic change and an increase in sea surface temperatures to favour a hospitable environment for *V. cholerae*, which could have

contributed to the displacement of this pathogen to more northern areas [10]. For that reason, a future increase in the frequency of isolation of this pathogen in microbiological samples might be expected.

Clinicians should be aware that non-O1/O139 *V. cholerae* might be the cause of extra-intestinal infections in patients exposed to fresh or marine water, especially if they have an underlying medical condition. Thus, *V. cholerae* should be taken into account in the differential diagnosis of ear infections, even in healthy people.

## ACKNOWLEDGEMENTS

Authors wish to acknowledge García-Perez A. and de Pablos M. for their microbiological support.

## FUNDING

Fundings provided by ISCIII, proyect "RD16/0027/0002" (Red de Enfermedades Tropicales, Subprograma RETICS del Plan Estatal de I+D+I 2013-2016) y por FEDER.

## CONFLICT OF INTEREST

The authors declare that they have no conflicts of interest

## REFERENCES

1. Ali M, Nelson AR, Lopez AL, Sack DA. Updated Global Burden of Cholera in Endemic Countries. *PLoS Negl Trop Dis.* 2015;9(6): e0003832. PMID:26043000
2. Dechet AM, Yu PA, Koram N, Painter J. Nonfoodborne Vibrio Infections: An Important Cause of Morbidity and Mortality in the United States, 1997-2006. *Clin. Infect. Dis.* 2008;46(7):970-6. PMID: 18444811
3. Romero Gómez MP, García-Perea A, Ruiz Carrascoso G, Bajo MA, Mingorance J. Campylobacter fetus Peritonitis and Bacteremia in a Patient Undergoing Continuous Ambulatory Peritoneal Dialysis. *J. Clin. Microbiol.* 2010;48(1):336-7. PMID: 19889904
4. Wayne PA. CLSI Guideline M45. Methods for Antimicrobial Dilution and Disk Susceptibility Testing of Infrequently Isolated or Fastidious Bacteria, 3rd Edition. Clinical and Laboratory Standards Institute, 2016.
5. Rozemeijer W, Korswagen LA, Voskuyl AE, Budding AE. *Vibrio cholerae* non-O1 non-O139 infection in an immunocompromised patient returning from Spain, July 2009. *Euro Surveill.* 2009;14(32). PMID: 19679033
6. Aguinaga A, Portillo ME, Yuste JR, del Pozo JL, García-Tutor E, Pérez-Gracia JL, et al. Non-O1 *Vibrio cholerae* inguinal skin and soft tissue infection with bullous skin lesions in a patient with a penis squamous cell carcinoma. *Ann Clin Microbiol Antimicrob.* 2009;8(1):17. PMID: 19454006

7. Garay E, Arnau A, Amaro C. Incidence of *Vibrio cholerae* and related vibrios in a coastal lagoon and seawater influenced by lake discharges along an annual cycle. *Appl. Environ. Microbiol.* 1985;50(2):426–30. PMID: 4051487
8. Deshayes S, Daurel C, Cattoir V, Parienti JJ, Quilici ML, Blanchardière A. Non-O1, non-O139 *Vibrio cholerae* bacteraemia: case report and literature review. *SpringerPlus.* 2015; 4: 457. PMID: 26543710
9. Rosenfeld RM, Schwartz SR, Cannon CR, Roland PS, Simon GR, Kumar KA, et al. Clinical Practice Guideline: acute otitis externa. *Otolaryngol Head Neck Surg.* 2014 Feb;150(1 Suppl):S1–S24. PMID: 24491310
10. Vezzulli L, Grande C, Reid PC, Hélaouët P, Edwards M, Höfle MG, et al. Climate influence on *Vibrio* and associated human diseases during the past half-century in the coastal North Atlantic. *Proc Natl Acad Sci USA.* 2016; 113(34):E5062–71. PMID: 26543710