

Clinical-Pathologic Conference

María José Galindo García^{1*}
Martha Kestler^{2,3,*}
Patricia Muñoz^{2,3,4,5}
Emilio Bouza^{2,3,4,5}

Severe bacterial non-AIDS infections in HIV women

¹Infectious Disease Department, Hospital Clínico de Valencia. Spain.

²Clinical Microbiology and infectious Diseases Department. Hospital General Universitario Gregorio Marañón, Madrid, Spain.

³Instituto de Investigación Sanitaria Gregorio Marañón, Madrid, Spain

⁴Department of Medicine, School of Medicine, Universidad Complutense de Madrid (UCM), Spain.

⁵CIBER de Enfermedades Respiratorias (CIBERES CB06/06/0058), Madrid, Spain

Article history

Received: 8 August 2018; Revision Requested: 21 September 2018; Revision Received: 19 October 2018; Accepted: 24 October 2018

PRESENTATION OF CASE (DR. MARÍA JOSÉ GALINDO)

The patient was a forty eight year old female, with history of HIV diagnosed on 1991 and currently on combined antiretroviral therapy with Kivexa and Edurant. She has a good antiviral compliance and four months before the current episode she presented a CD4 count of 1,028 cells/mcl, a CD4/CD8 ratio of 1.32 and a viral load of 103 copies/ml. She is an active smoker and at the age of 36 was diagnosed with a low-grade squamous intraepithelial lesion of the cervix that required surgical resection on July 2017.

On January 2018 the patient presented a flu like syndrome that was handle on the community with symptomatic treatment. Forty eight hours previous to the admission, the patient attended to the GP office with general malaise, fever and neck stiffness. The patient was referred to the hospital emergency department on February 15th 2018 with clinical suspicion of meningitis.

Physical examination. Temperature was 39°C; Blood pressure 100/60 mmHg; Heart rate 132 b/mn. The patient was conscious, desoriented, eupneic at rest, sweaty and presented neck stiffness. Skin and mucous membranes were well colored and the patient was well hydrated. Yugular pulse was normal. There were no heart murmurs or extra tones. Lung examination was normal. The abdomen was soft, with no masses or organ enlargement and normal bowels sounds.

Initial laboratory data. Haemoglobin 8.6 g/Dl. Mean Corpuscular Volume 92. Platelet count $22 \times 10^9/l$. White Blood

Count 10,120/uL (Lymphocytes 14.3%). Coagulation tests without abnormalities. CRP: 368.1 mg/l. Venous blood data: Glucose 146 mg/dL. Urea: 59 mg/dl. Creatinine: 0.75 mg/dl. Na: 139 mmol/L, K: 4.07 mmol/L.

Images. PA Chest X-ray (Day 0) is shown in figure 1.

The patient was admitted in the intensive care unit due to sustained hypotension requiring vasoactive drugs and I.V. fluid infusion. A lumbar puncture was reported as follows: Glucose= 0 mg/dl; proteins= 475 mg/dl; 20 red cells/ul; 2 leucocytes/ul.

At this point empirical antibiotic treatment was initiated with linezolid 600 mg iv /BD, ampicillin 2 g iv/QDS; acyclovir 500 mg iv/TDS, cefotaxime 4 g iv/QDS, and dexamethasone 8 mg iv/TDS.

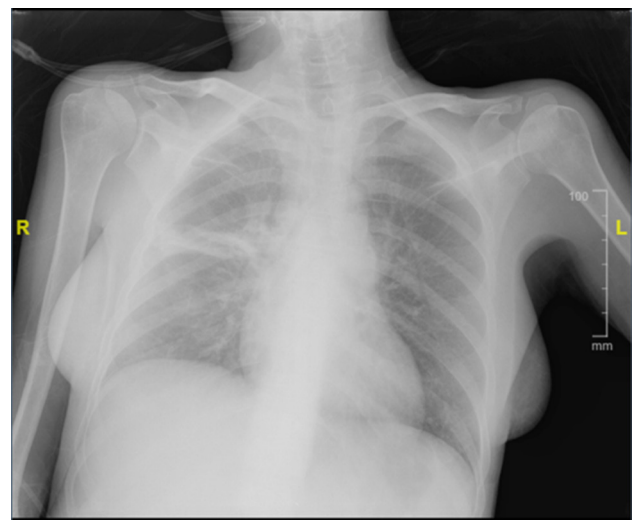


Figure 1 | PA Chest X ray on admission

Correspondence:

María José Galindo García
Infectious Disease Unit, Internal Medicine Service.
Hospital Clínico de Valencia, Spain

Emilio Bouza
Instituto de Investigación Sanitaria Gregorio Marañón
C/ Dr. Esquerdo, 46
28007 Madrid, Spain
Phone: +34- 91- 3721721/Fax: +34-91- 504 49 06
E-mail: emilio.bouza@gmail.com

*Both to be considered First authors

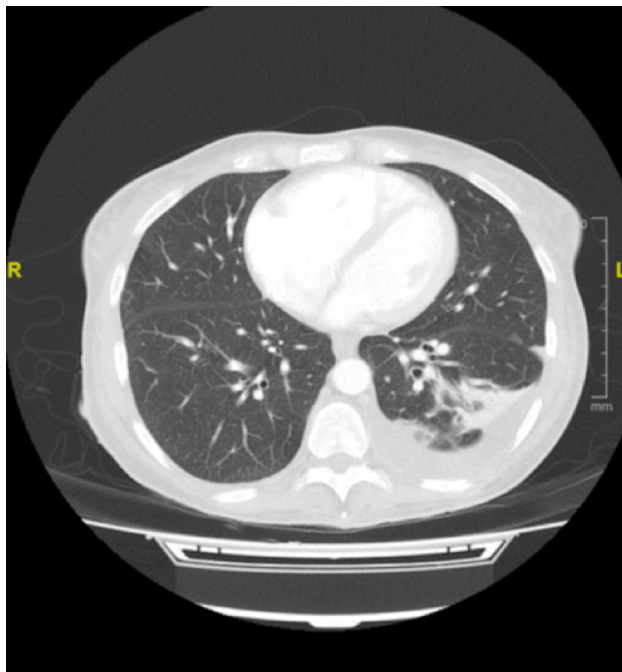

Figure 2 | Chest CT

Forty eight hours after admission the patient was hemodynamically stable, and afebrile. Antibiotic therapy was adjusted to only high dose cefotaxime, and the patient was transferred to the infectious diseases ward.

During her ID ward admission, the patient spiked temperature and presented an episode of intense chills. A set of blood cultures were sent to the laboratory and linezolid was added to the antibiotic treatment. On physical examination a new pan-systolic murmur along the tricuspid region was noticed. An echocardiography showed an image compatible with a vegetation of 23mmx13mm, pedunculated, very mobile on the pulmonary valve. The patient was clinically stable, although spiked temperature; therefore, antibiotic treatment was re-assessed and ceftriaxone, gentamicin and linezolid were prescribed. Within the infective endocarditis extension assessment a chest and abdomen CT scan was performed (figure 2).

Chest and abdomen CT reported a left pleural effusion with a passive atelectasis on the right superior and medial lobe, a cavitated nodule of 2 cm in the anterior segment of the left superior lobe; which could correspond with a septic emboli, and splenomegaly of 14 cm.

DIFFERENTIAL DIAGNOSIS OF THE PATIENT (DR. MARTHA KESTLER)

I am totally unaware of the diagnosis of this patient. In my opinion, this patient who refers a 48-year-old HIV positive female, with history of smoking was admitted with fever

and confusion. Her CD4 lymphocyte cell count was 1028 cel/mm³ and she was on antiviral therapy. Her clinical evaluation on admission was that of possible meningitis with severe community acquired pneumonia. She was treated with a high dose intravenous dexamethasone and cefotaxime. Her confusion resolved and his respiratory distress improved on medical therapy. However, on day 3, she had a new heart murmur and persistent temperature spikes suggesting ongoing bacteremia. An echocardiography demonstrated a large vegetation, and a native pulmonary valve infective endocarditis was diagnosed.

My main question, therefore, is to speculate on the causal microorganism. I was not told if the patient had previous history of recent travel abroad, nor the patient profession or if she owned any pets.

I will first discuss the hypothesis that the patient's condition is the result of an opportunistic infectious disease; although the patient compliance has not been specifically mentioned, the last analytical control revealed a high CD4 (1,028 cel) count and a low viral load (103 copies). Current guidelines [1] state that the aim of the combined antiretroviral therapy (cART) is to reach a viral load less than 50 copies/ml; which is associated with maximum immunological recovery and prevents the emergence of resistance mutations; an isolated transient viral load increase ("blip") has no clinical impact, but closer monitoring is recommended. It should be considered that the number of CD4+ lymphocytes is the fundamental indicator of immune status [1], and it should be used to stage HIV infection, assess the risk of comorbidity, the vulnerability to certain opportunistic infections; Therefore, we can considered that this patient has a good immunological response to treatment and a low risk to develop opportunistic infections.

Altogether with the acute onset of the symptoms, the findings on the CSF, the good clinical response to antibiotic treatment, and the community setting, I would like to discuss the possibility that we are dealing with a severe bacterial non-AIDS infection.

With the introduction of combined antiretroviral therapy (cART), diseases that define the acquired immune deficiency syndrome (AIDS) have become increasingly less common in patients with well-controlled viremia [2]. During the past years it has become apparent that typical AIDS-defining diseases have been substituted by other comorbid conditions; often referred to as non-AIDS defining conditions such as, atherosclerotic cardiovascular disease, non-AIDS defining malignancies, liver disease, and renal disease. New bacterial non-opportunistic infections requiring hospitalization are becoming increasingly more common [3].

In a large, multinational observational study, Sogaard, et al [4], assessed the risk of first hospitalization due to bacterial non-AIDS infections and found an incidence rate (IR) of 7.67 per 1000 PYFU. The most frequent infections were pneumonia (IR=5.36), bacteremia (IR=1.14), and pyelonephritis (IR=0.67). Overall mortality rate was 7.4 per 100 PYFU (95% CI 5.3-9.5).

In general, the clinical presentation of bacterial CAP in HIV-infected patients is similar to that occurring in cases that

are not HIV infected [5]. Regarding etiology, the spectrum of pathogens causing pulmonary infections in HIV-infected persons is vast, differs in various geographic areas, and has changed over the evolution of the epidemic because of the introduction of prophylaxis and cART. However, bacterial infections are still the main cause of hospitalization and a major cause of death in this population [4]. An observational study that included 9,101 hospitalized HIV-infected patients in the United States (from 2004 to 2008) found that non-recurrent bacterial pneumonia was the second most common cause of death accounting for 20% of the deaths, behind sepsis which accounted for 38% of the observed deaths [6]. In general, the bacterial cause of CAP is similar in HIV-infected and HIV-uninfected individuals. Polymicrobial infections do occur, and coinfections with common bacterial pathogens and opportunistic pathogens, have been described. The most common bacterial cause of CAP in HIV infected persons are *Streptococcus pneumoniae*, *Haemophilus influenzae* and *Staphylococcus aureus* [4,5,7].

S. pneumoniae is by far, the most common cause of bacterial pneumonia in HIV-infected individuals, being implicated in some 40% of cases in which a microbiological diagnosis is made, and 70% of cases with bacteremic pneumonias [7]. Although *S. pneumoniae* most of the times is associated with an uncomplicated upper and lower respiratory tract infection; a more serious manifestation of infection characterized by pneumonia with bacteremia and/or meningitis (Invasive Pneumococcal Disease; IPD) is an important complication, especially in those infected with HIV, even in the era of cART [8]. A case-control study that was carried out in Hospital Clinic, Barcelona, Spain; found that 50% of the HIV patients with pneumococcal CAP, also had bacteremia, although it is important to highlight that the presence of HIV infection did not influence the clinical outcomes of CAP [9]. Although *S. pneumoniae* is one of the most common Gram-positive pathogenic bacteria in humans, very rarely (<3%) does pneumococcal infections cause endocarditis of native heart valves [10, 11]. However, when pneumococcal endocarditis is present, Austrian triad (meningitis, pneumonia and infective endocarditis) is common among these patients with an incidence as high as 60% [12].

H. influenzae, account for approximately 10% to 15% of all cases of bacterial pneumonia with known microbiological cause [13]. However, it is more frequent among patients with advanced HIV disease and usually presents as a subacute infection. Radiographic presentation is commonly a diffuse pulmonary infiltrate, and the mortality rate is not higher with this form of pneumonia than occurring in the general population [14].

S. aureus is another common cause of bacterial CAP [7], accounting around 5% of the cases although it is most common among IDU persons, such infections are associated with endocarditis, with or without septic pulmonary emboli, even in patients without prior evidence of cardiac valvular disease. Another important epidemiological background to consider *S. aureus* CAP is recent viral, especially influenza, infection. Wolter et al [15], found that 30.3% the influenza patients (207/683) admitted on ICU, had a bacterial co-infection, and *S. aureus* was the most frequent bacteria isolated (37%) followed by *S.*

pneumoniae (12.3%) [16]. Unlike pneumococcal infection, *S. aureus* is a frequent cause of infective endocarditis, accounting 23.6% of all cases of IE of the National Spanish cohort [17], with a particularly high prevalence rate among IDU patients.

DIAGNOSIS (DR. MARÍA JOSÉ GALINDO)

In my opinion, the first diagnostic possibility for this patient is that of *S. pneumoniae* disease (Austrian syndrome)

Although, I find less attractive the possibility of other bacterial infections, such as those caused by *S. aureus* and *H. influenzae*, they should be considered as well.

EVOLUTION OF THE PATIENT (DR. MARTHA KESTLER)

A *S. pneumoniae* was isolated on blood and cerebrospinal fluid cultures.

Heart valve replacement was discarded and completed four weeks of combined antibiotic therapy with ceftriaxone, gentamicin and tedizolid. Subsequently, the patient presented a good clinical outcome and was discharged with cefditoren.

Austrian syndrome is a triad of pneumococcal pneumonia, endocarditis and meningitis, that was first described in 1862 by Heschl, but it was Robert Austrian in 1957, who highlighted the affinity of *S. pneumoniae* to the aortic valve and the simultaneous presence of meningitis. Austrian syndrome is a clinical rarity with an incidence of 1.2% among those with infectious endocarditis [10], and a very high mortality. Early diagnosis is essential for optimal treatment and a good prognosis.

Traditional risk factors for pneumococcal infection include alcoholism, chronic lung disease, prolonged steroid use, diabetes mellitus, haematological malignancies and chronic renal disease [4]. Patients with HIV infection/acquired immunodeficiency syndrome have a higher mortality from bacteraemic pneumococcal pneumonia than non-HIV infected patients [14].

Finally, the issue of prophylaxis against pneumococcal infection in immunocompromized hosts has been the subject of much debate. Use of the 23-valent pneumococcal polysaccharide vaccine has been shown to be protective in HIV positive patients in preventing invasive pneumococcal infection, but these findings are based largely on case-controlled and observational studies [18]. Current expert opinion advocates the use of the 13-valent pneumococcal conjugated vaccine in all persons with HIV infection, followed 8 weeks later by revaccination with 23-valent pneumococcal polysaccharide vaccine [18].

FINAL DIAGNOSIS

S. pneumoniae disease (Austrian syndrome)

FUNDING

None to declare

CONFLICT OF INTEREST

The authors declare that have no conflict of interest.

REFERENCES

- Executive summary of the GeSIDA/National AIDS Plan consensus document on antiretroviral therapy in adults infected by the human immunodeficiency virus (updated January 2018). *Enferm Infecc Microbiol Clin*, 2018. doi: 10.1016/j.eimc.2018.02.010
- Huang, L. and K. Crothers, HIV-associated opportunistic pneumonias. *Respirology*. 2009;14(4): 474-85. doi: 10.1111/j.1440-1843.2009.01534.x
- Deeks SG, Lewin SR, Havlir DV. The end of AIDS: HIV infection as a chronic disease. *Lancet*. 2013; 382(9903): 1525-33. doi: 10.1016/S0140-6736(13)61809-7
- Sogaard OS, Reekie J, Ristola M, Jevtovic D, Karpov I, Beniowski M, et al. Severe bacterial non-aids infections in HIV-positive persons: incidence rates and risk factors. *J Infect*. 2013; 66(5): 439-46. doi: 10.1016/j.jinf.2012.12.012.
- Lamas CC, Coelho LE, Grinsztejn BJ, Veloso VG. Community-acquired lower respiratory tract infections in HIV-infected patients on antiretroviral therapy: predictors in a contemporary cohort study. *Infection*. 2017; 45(6): 801-809. doi: 10.1007/s15010-017-1041-0.
- Kim JH, Pseudos G Jr, Gonzalez E, Singh S, Kilayko MC, Sharp V. All-cause mortality in hospitalized HIV-infected patients at an acute tertiary care hospital with a comprehensive outpatient HIV care program in New York City in the era of highly active antiretroviral therapy (HAART). *Infection*. 2013; 41(2): 545-51. doi: 10.1007/s15010-012-0386-7
- Feldman C, Anderson R. HIV-associated bacterial pneumonia. *Clin Chest Med*. 2013; 34(2): 205-16. doi: 10.1016/j.ccm.2013.01.006.
- van Aalst M, Lötsch F, Spijker R, van der Meer JTM, Langendam MW, Goorhuis A et al., Incidence of invasive pneumococcal disease in immunocompromised patients: A systematic review and meta-analysis. *Travel Med Infect Dis*. 2018;24: 89-100. doi: 10.1016/j.tmaid.2018.05.016.
- Cilloniz C, Torres A, Manzardo C, Gabarrús A, Ambrosioni J, Salazar A, et al. Community-Acquired Pneumococcal Pneumonia in Virologically Suppressed HIV-Infected Adult Patients: A Matched Case-Control Study. *Chest*. 2017; 152(2):295-303. doi: 10.1016/j.chest.2017.03.007.
- de Egea V, Muñoz P, Valerio M, de Alarcón A, Lepe JA, Miró JM, et al. Characteristics and Outcome of Streptococcus pneumoniae Endocarditis in the XXI Century: A Systematic Review of 111 Cases (2000-2013). *Medicine (Baltimore)*. 2015; 94(39):e1562. doi: 10.1097/MD.0000000000001562
- Munoz P, Sainz J, Rodríguez-Creixéms M, Santos J, Alcalá L, Bouza E. Austrian syndrome caused by highly penicillin-resistant Streptococcus pneumoniae. *Clin Infect Dis*. 1999; 29(6): 1591-2. DOI: 10.1086/313542
- Zachariah D, Manga P. HIV and invasive pneumococcal infection. *Int J Cardiol*. 2015; 198:157-88. doi: 10.1016/j.ijcard.2015.06.167.
- Cordero E, Pachón J, Rivero A, Girón JA, Gómez-Mateos J, Merino MD, et al. Haemophilus influenzae pneumonia in human immunodeficiency virus-infected patients. The Grupo Andaluz para el Estudio de las Enfermedades Infecciosas. *Clin Infect Dis*. 2000; 30(3):461-5. DOI: 10.1086/313690
- Benito N, Moreno A, Miro JM, Torres A. Pulmonary infections in HIV-infected patients: an update in the 21st century. *Eur Respir J*. 2012;39(3):730-4. doi: 10.1183/09031936.00200210
- Wolter N, Cohen C, Tempia S, Madhi SA, Venter M, Moyes J, et al. HIV and influenza virus infections are associated with increased blood pneumococcal load: a prospective, hospital-based observational study in South Africa, 2009-2011. *J Infect Dis*. 2014;209(1):56-65. doi: 10.1093/infdis/jit427
- Rice TW, Rubinson L, Uyeki TM, Vaughn FL, John BB, Miller RR 3rd, et al. Critical illness from 2009 pandemic influenza A virus and bacterial coinfection in the United States. *Crit Care Med*. 2012;40(5):1487-98. doi: 10.1097/CCM.0b013e3182416f23
- Munoz P, Kestler M, De Alarcon A, Miro JM, Bermejo J, Rodríguez-Abella H, et al. Current Epidemiology and Outcome of Infective Endocarditis: A Multicenter, Prospective, Cohort Study. *Medicine (Baltimore)*. 2015;94(43):e1816 doi: 10.1097/MD.0000000000001816
- Lee KY, Tsai MS, Kuo KC, Tsai JC, Sun HY, Cheng AC, et al. Pneumococcal vaccination among HIV-infected adult patients in the era of combination antiretroviral therapy. *Hum Vaccin Immunother*. 2014;10(12):3700-10. doi: 10.4161/hv.32247